MUSCULOSKELETAL INJURIES

D.Yegon

MUSCULOSKELETAL INJURIES

- Are traumatic events due to

a) Fractures

b) Dislocation

c) Associated soft tissues injuries

- A ***contusion*** is a soft tissue injury produced by blunt force, such as a blow, kick, or fall.
- Many small blood vessels rupture and bleed into soft tissues (ecchymosis, or bruising).
- A hematoma develops when the bleeding is sufficient to cause an appreciable collection of blood.
- Local symptoms (pain, swelling, and discoloration) are controlled with intermittent application of cold. Most contusions resolve in 1 to 2 weeks.

- A ***strain*** is a “muscle pull” caused by overuse, overstretching, or excessive stress.
- The C/M of strain and sprain are similar i.e. pain, edema, decreased function and contution.
- The patient experiences soreness or sudden pain, with local tenderness on muscle use and isometric contraction.

Symptoms Of Calf Strain
Calf Muscle
Grade I
Grade II
Grade III
For Information, Visit: www.epainassist.com

- **A sprain** is an injury to the ligaments surrounding a joint that is caused by a wrenching or twisting motion.
- The function of a ligament is to maintain stability while permitting mobility.
  - 1st degree – stretched
  - 2nd degree – partially torn
  - 3rd degree – completely torn
- An x-ray should be obtained to rule out bone injury.
- Avulsion fracture (in which a bone fragment is pulled away by a ligament or tendon) may be associated with a sprain.
- Most common are the fingers, wrist, ankle, and knee

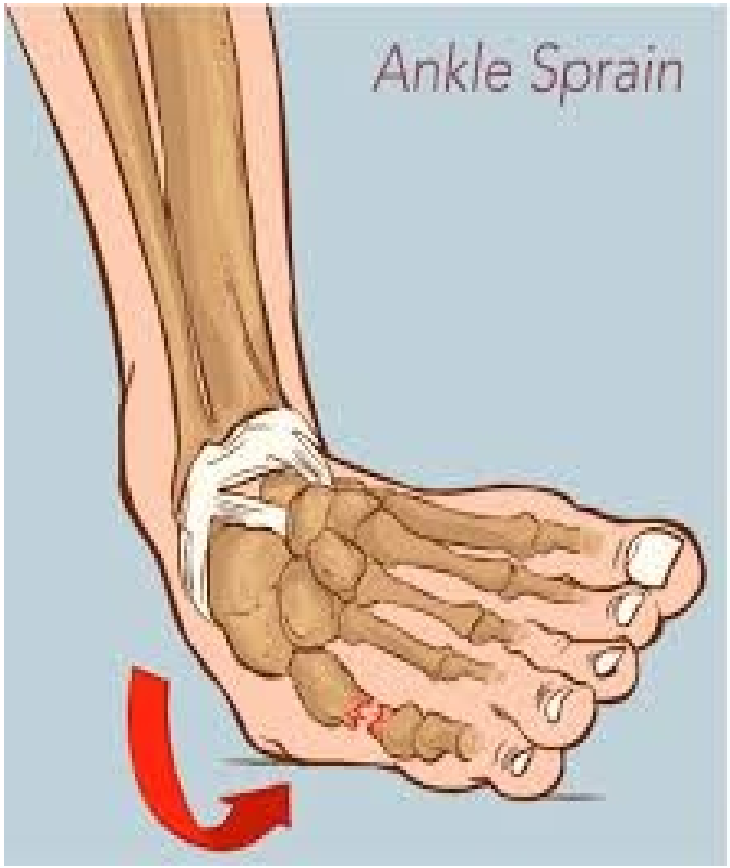
Ankle Sprain

Management

- Treatment of contusions, strains, and sprains consists of;
  - stop activity and limiting movement.
  - elevating the affected part
  - applying cold
  - compression bandage.
  - Analgesia if needed.

DISLOCATIONS

- When the bones at a joint are no longer in proper contact.
- Can be caused by severe twisting or indirect force, or even a muscular contraction
- Most frequently dislocated joints
  - Shoulder
  - Elbow
  - Thumb
  - Finger
  - Jaw
  - Knee

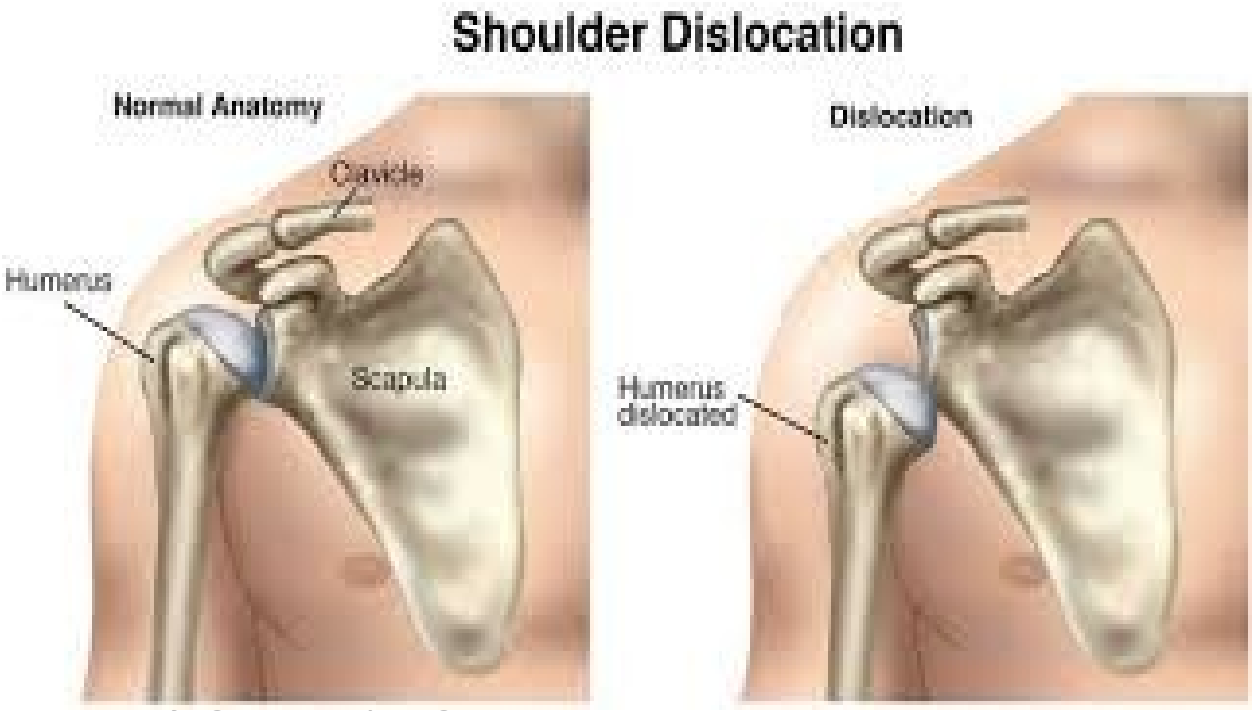

Signs and Symptoms of a Dislocation

- Deformity or abnormal appearance
- Pain and tenderness aggravated by movement
- Loss of normal function
- Joint may be locked in one position
- Swelling of the joint

General Treatment Principles

- Stop the activity.
- Survey the injured area.
- First Aid if qualified.
- Get help if not.
- Determine if additional medical attention is necessary.
- Reduction under anaesthesia
- Immobilization is done by splinting or bandaging
- Physiotherapy
- Pain management.

FRACTURES

- A fracture is condition in which there is a break in the continuity of the bone.
- It can occur as a result of high force impact or stress.

Etiology/predisposing factors

- **Trauma.** A fall, a motor vehicle accident, or a tackle during a football game can all result in fractures.
- **Osteoporosis.** This disorder weakens bones and makes them more likely to break. Leading to pathological fractures.
- **Overuse.** Repetitive motion can tire muscles and place more force on bone. This can result in stress fractures. Stress fractures are more common in athletes.
- **Treatment modalities-** some drugs used cause demineralization of the bones

Clinical features

- Local trauma
- Deformity
- Pain
- Erythema
- Loss of function
- Impaired mobility
- crepitus

Types of fractures

Complete fractures – this involves a break across the entire cross-section of the bone. They are frequently displaced that is removed from the normal position. Examples;

- ✓ **Comminuted fracture** – this is the bone fracture which produces several bone fragments.
- ✓ **Linear fracture** – it is a break that is parallel to the bone's long axis
- ✓ **Transverse fracture** – it is a break at right angle to the bone's long axis

Transverse Fracture

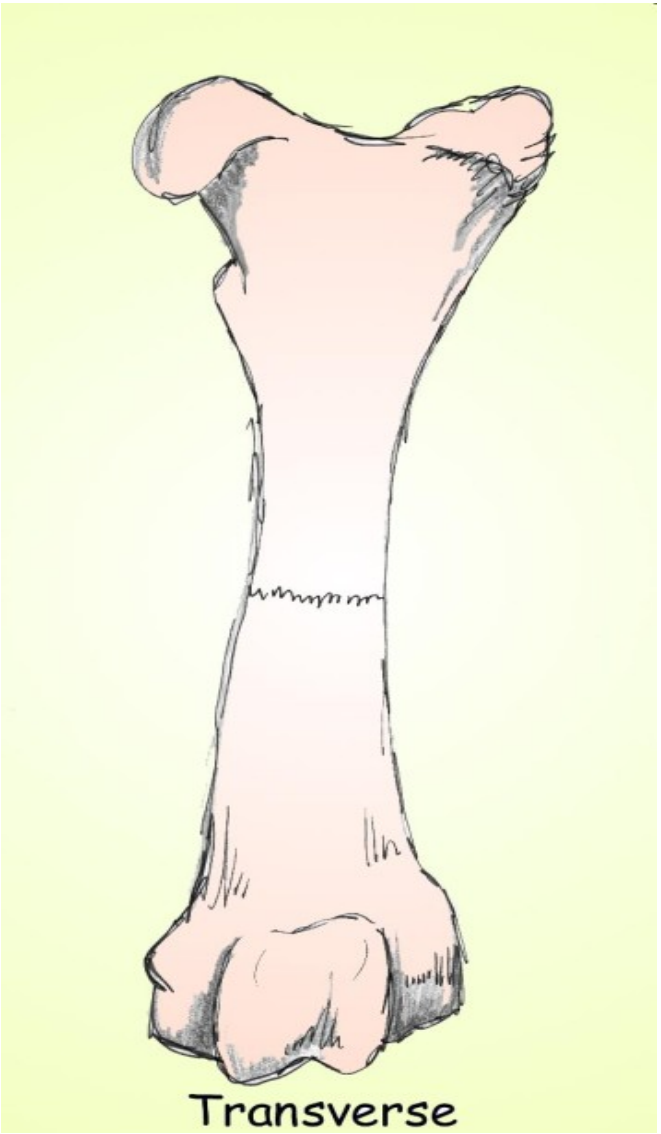

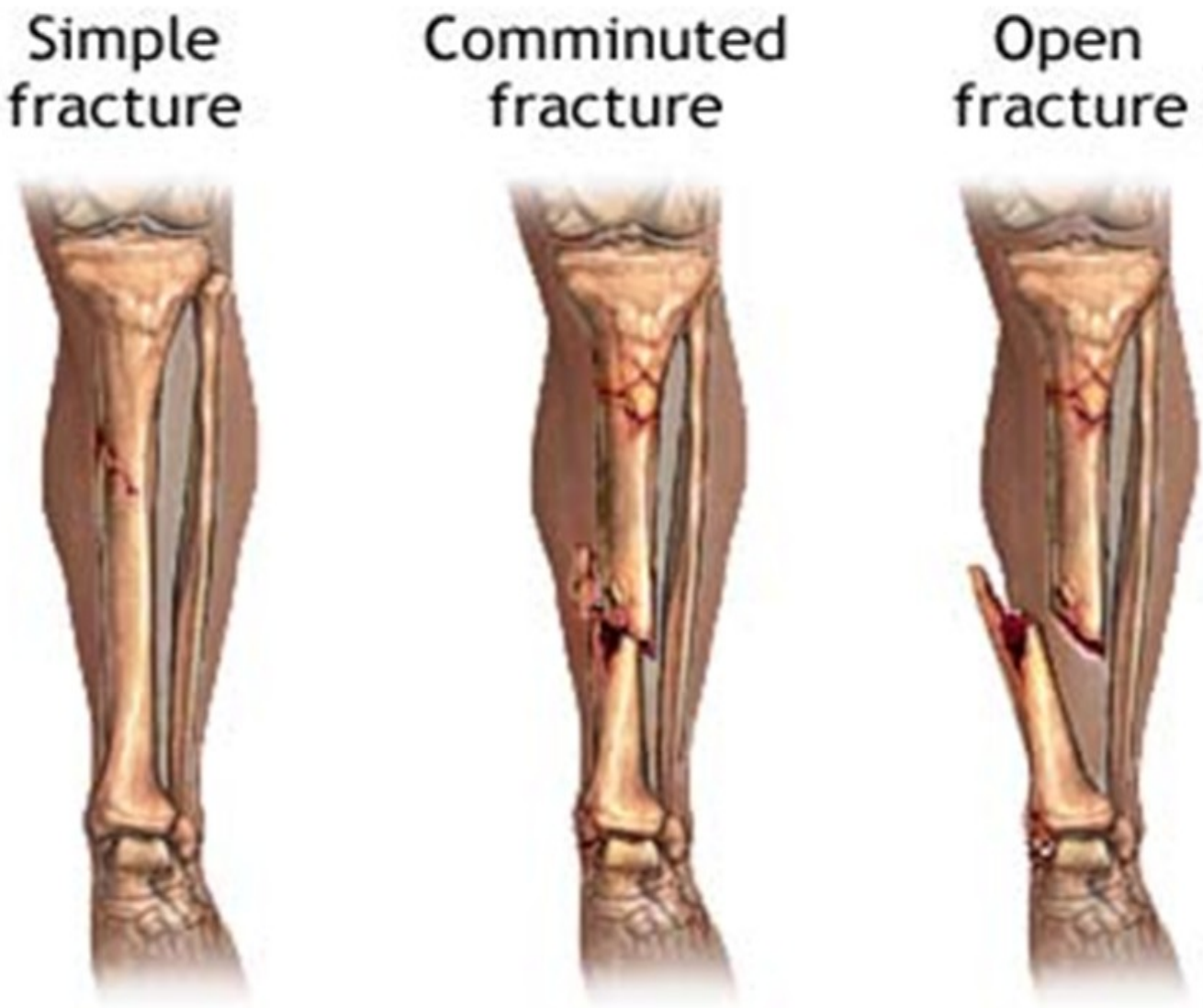
Simple fracture
Comminuted fracture
Open fracture

- ✓ **Oblique fracture** – it is a fracture that is diagonal to a bone's long axis
- ✓ **Spiral fracture** – it is a fracture where at least one part of the bone is being twisted
- ✓ **Multiple Fracture-** where there are three or more fracture fragments in a single bone. The fracture lines are not interconnect. The fracture lines may be of any shape. These are two or more completely independent fractures affecting the same bone, e.g oblique fracture of proximal and distal femur

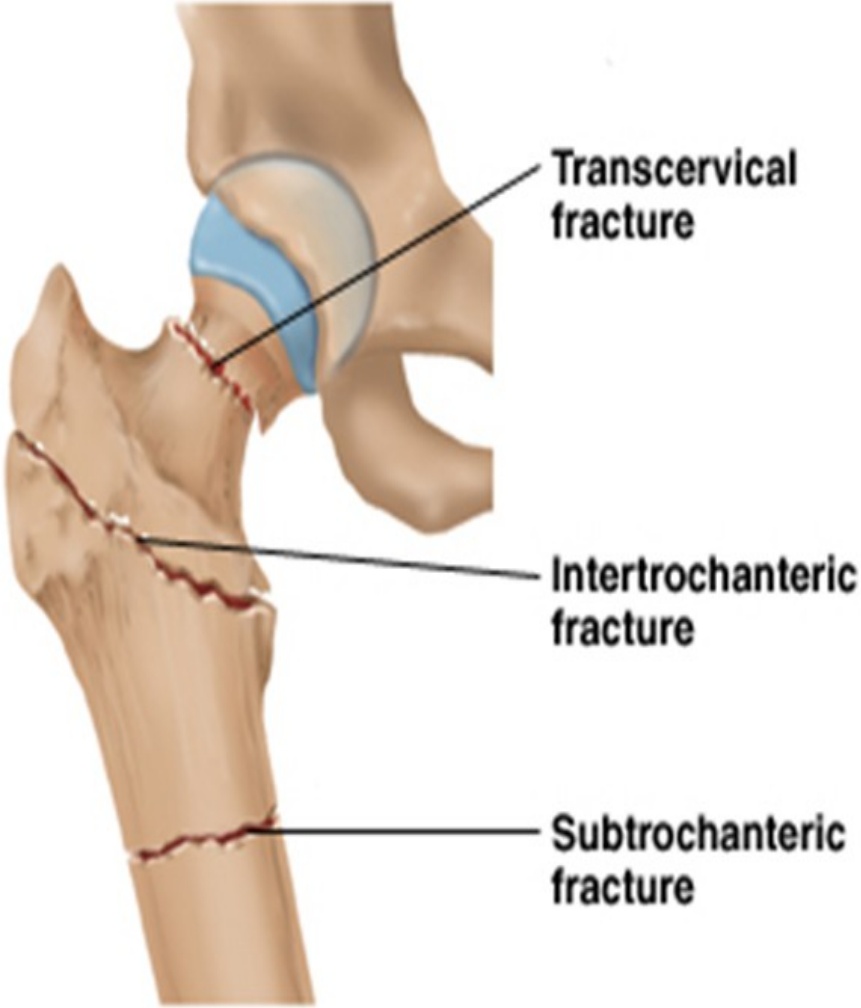

Multiple Fracture

Spiral fracture of femur

Fibula

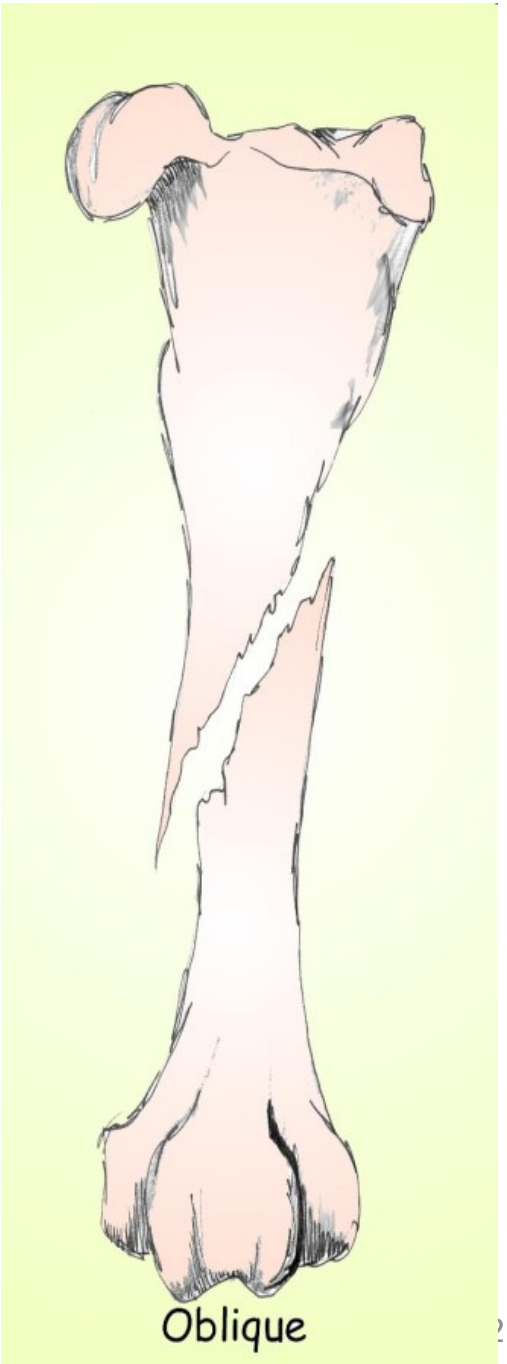

- ✓ **Impacted fracture -** it is a break caused when bone fragments are driven into another bone fragment

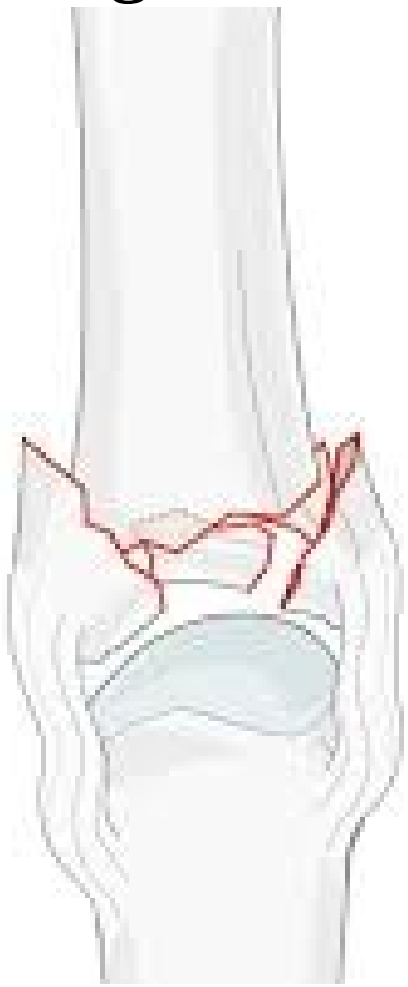

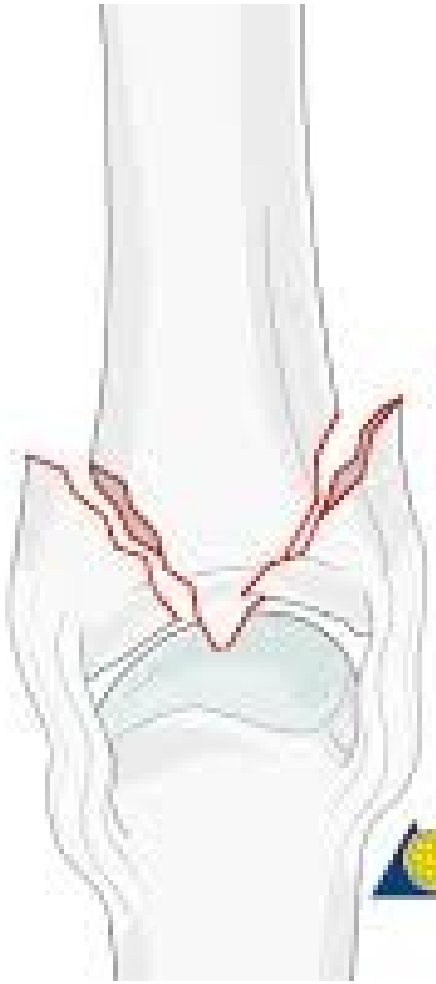

Incomplete fractures- An incomplete fracture implies that a bone has not completely lost continuity; some portion of the bone remains intact. There are several types of incomplete fractures, examples;

- **Avulsion Fracture-** A separation of a small bone fragment from the bone where a tendon or ligament is attached.
- **Articular fracture-** Involves a joint surface. Articular is cartilage at the end of the long bones where bones articulate, or meet.

- **Greenstick fracture –** it is a fracture in which one side of bone is broken and the other side is bent
- **Fissure Fracture-** Cracks or fissure lines will occur when direct trauma is applied to any long or flat bone.
- **Depression Fracture-**Depression fractures represent areas in which multiple fissure fracture lines intersect. The fragments of the bone are driven inwards.
- **Hairline fracture.** A very thin crack or break in the bone
- **Stress fracture**. Fracture caused by repetitive stress to a bone

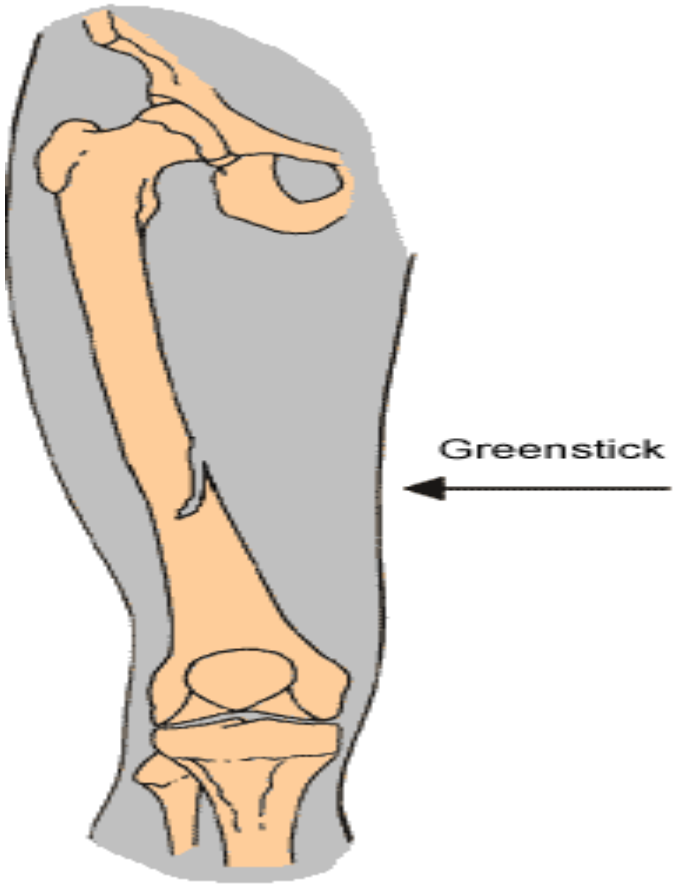
Greenstick

Depression fracture

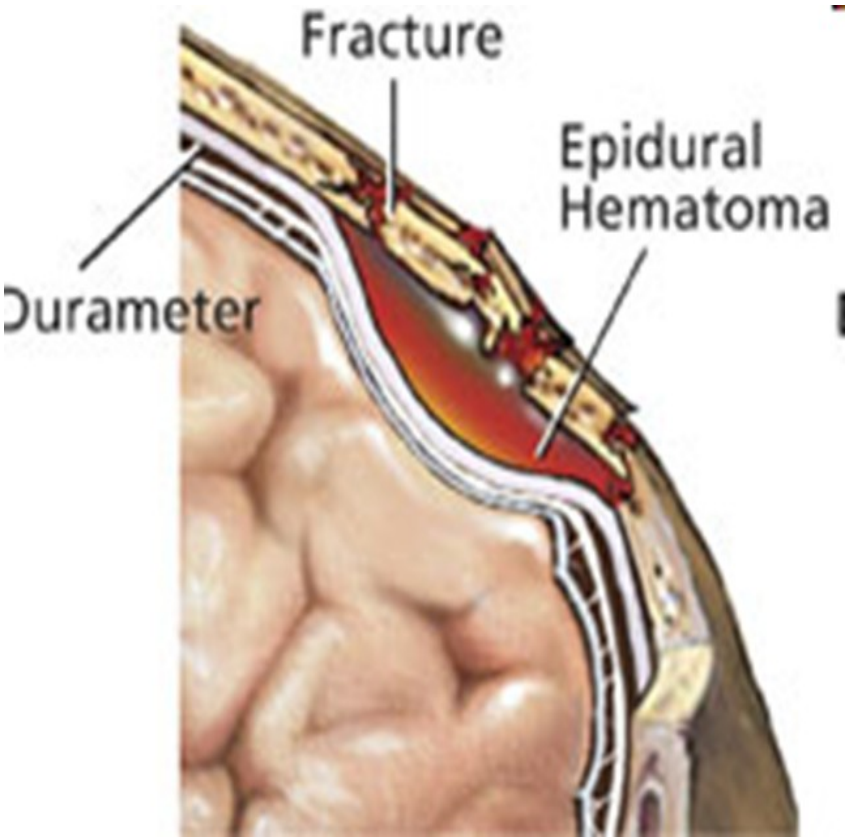

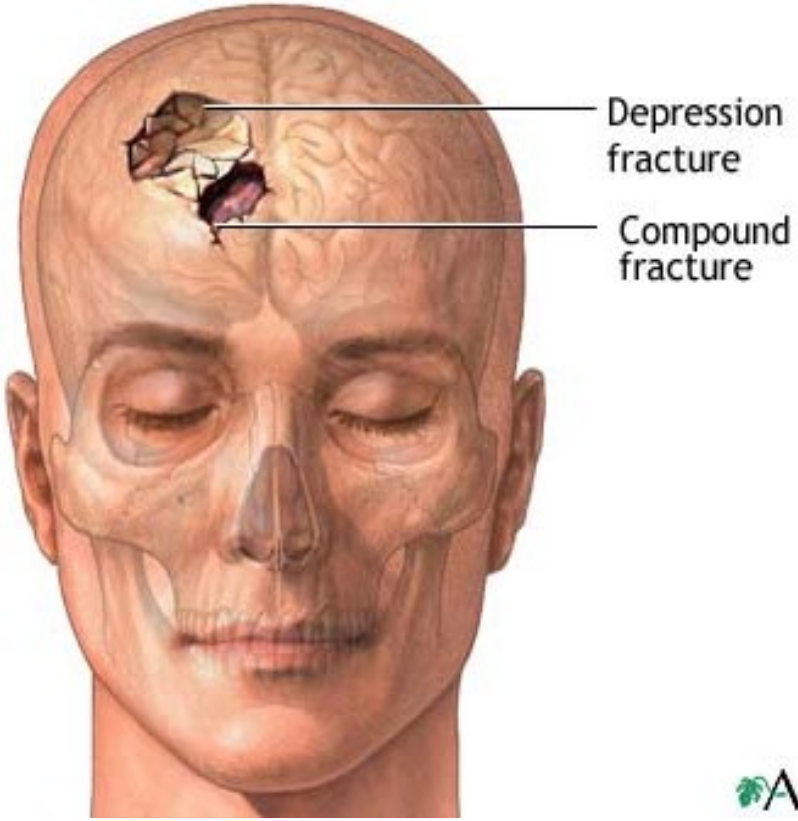

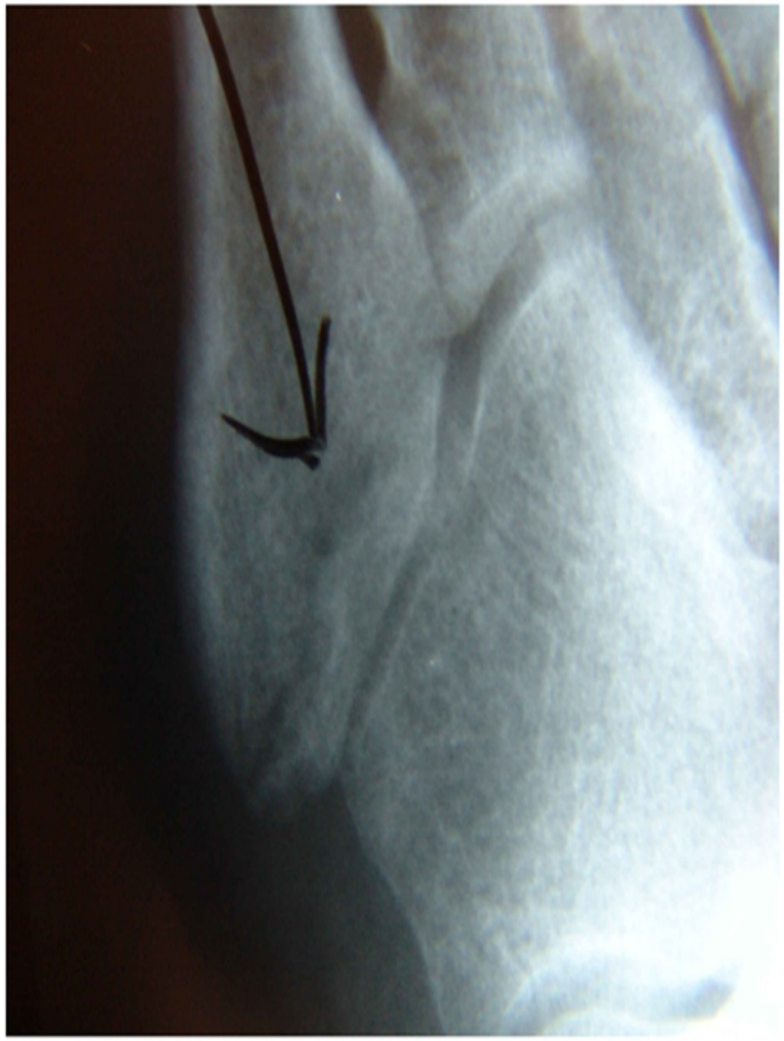

Hairline fracture of the foot

An open fracture –it is also refered to as ***compound or complex.*** It is the one in which the skin or mucous membrane wound extend to the fractured bone or fractured hematoma is exposed. It is categorized in the following way:

i. Grade1 –clean wound less than 1cm long
ii. Grade 2 –large wound without extensive soft tissue damaged
iii. Grade3 –highly contaminated, has extensive soft tissue damaged which is most severe

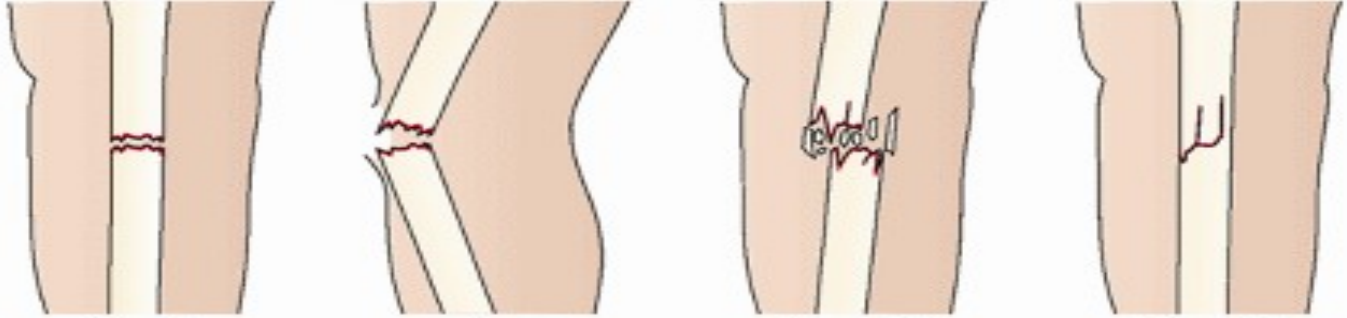

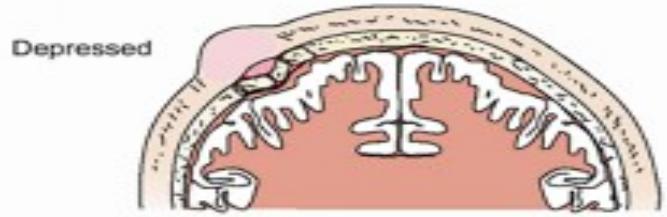

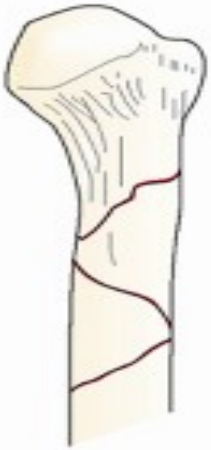

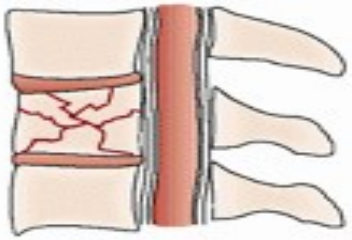

Avulsion—a pulling away of a fragment of bone by a ligament or tendon and its attachment
Closed—a fracture that remains contained; does not break the skin
Comminuted—a fracture in which bone has splintered into several fragments
Compression—a fracture in which bone has been compressed (seen in vertebral fractures)
Depressed—a fracture in which fragments are driven inward (seen frequently in fractures of the skull and facial bones)
Epiphyseal—a fracture through the epiphysis
Greenstick—a fracture in which one side of a bone is broken and the other side is bent
Impacted—a fracture in which a bone fragment is driven into another bone fragment
Oblique—a fracture occurring at an angle across the bone (less stable than transverse)
Open—a fracture in which damage also involves the skin or mucous membranes
Pathologic—a fracture that occurs through an area of diseased bone (bone cyst, Paget's disease, bony metastasis, tumor); can occur without trauma or a fall
Spiral—a fracture twisting around the shaft of the bone
Transverse—a fracture that is straight across the bone

Diagnosis

History taking

X-rays

CT scan

MRI

Emergency/casualty management

First Aid principles with fractures

- Good first aid care of fractures is always important. First aid for fractures is all about immobilizing (limiting movement) the injury.
- Abnormal movement of the broken bones can increase pain and bleeding and cause damage of the tissues around the injury.

- This can lead to complications in the repair and healing of the injury later on.
- Splints can be purpose made or makeshift but will be effective if the injury is immobilized above and below the break to stop movement.

- Any external bleeding should be controlled.
- Complicated breaks where a limb is very deformed may need to be realigned before splinting and this is best done only by paramedics or medical staff.
- Other fractures of the body such as skull, ribs and the pelvis are all serious and should be managed by paramedics.

Management of fractures

- The principles of fracture treatment include
  - Reduction
  - Immobilization
  - Rehabilitation

REDUCTION

- Reduction of a fracture (“setting” the bone) refers to restoration of the fracture fragments to anatomic alignment and rotation.
- Either closed reduction or open reduction may be used to reduce a fracture

Closed Reduction.

- Closed reduction is accomplished by bringing the bone fragments into apposition (i.e, placing the ends in contact) through manipulation and manual traction.

- The extremity is held in the desired position, length and alignment while the physician applies a cast, splint, or other device. Reduction under anesthesia.
- The immobilizing device maintains the reduction and stabilizes the extremity for bone healing.
- X-rays are obtained to verify that the bone fragments are correctly aligned.
- Traction (skin or skeletal) may be used to effect fracture reduction and immobilization.

- **Traction-**is the application of a pulling force to an injured or diseased part of the body or an extremity while *Countertraction* pulls in the opposite direction.
- **Two types skin and skeletal traction.**

Indications

To reduce, align, and immobilize fractures

To minimize muscle spasms

Reduce bone deformity

Increase space between opposing forces(for orthopedic procedures)

NB; traction is used as a shorter intervention until other treatment modalities are possible

used to

- prevent or reduce pain and muscle spasm associated with lowback pain or cervical sprain (e.g., whiplash),
- immobilize a joint or part of the body,
- reduce a fracture or dislocation, and
- treat a pathologic joint condition (e.g., tumor, infection).

Principles of effective traction

Counter-traction- whenever traction is applied, counter-traction must be used to achieve effective traction

Skeletal traction is never interrupted

Weights are never removed unless intermittent traction is prescribed

Maintain the line of pull

The patient must be in good body alignment in the Centre of the bed

Ropes must be unobstructed in straight alignment

Weights must hang freely and not rest on the bed or floor

Knots on the rope must not touch the pulley or the foot of the bed

Skin traction- this is traction applied through the skin. Skin traction is generally less desirable due to the fact that skin can be injured when pressure is applied for extended periods of time.

- It works by applying weight to tape, sponge rubber, or canvas materials which have been attached to the skin surrounding the damaged body structure.
- The amount of weight which can be applied to skin traction is limited to the tolerance of the skin.

- Skin traction is used for the control of muscle spasm and to provide immobilization, in theatre during the procedure.
- If prolonged or heavy traction weight is needed then skeletal traction is usually used rather than skin traction.
- Traction must be applied in the direction and magnitude to obtain its desired effect. As soft tissue and muscle relax, the amount of weight required may change to maintain the desired pulling force.
- When traction is applied counter-traction needs to be considered. Counter-traction is force acting in the opposite direction; it is achieved by elevating the foot of the bed.

- **<u>Indication of skin traction</u>**

Children

Temporary traction - only a few days e.g. Preoperative

Small force required to maintain reduction <5 kg

- **<u>Contraindication of skin traction</u>**

- Force required > 5kg
- Skin damage or sepsis in area e.g. if the skin has abrasions, lacerations, dermatitis, impaired circulation, burns *etc*

Factors to consider when applying skin traction

- Any factor which might reduce the pull or alter the line of pull must be eliminated.
- Skin should be assessed for abrasions and circulatory problems before the application of skin traction, as it must be in a healthy condition to tolerate the traction.
- The patient should be in good body alignment in the middle of the bed.
- Ropes and weights must be unobstructed.
- Knots in the rope or footplate must not touch the pulley or the foot of the bed.

Types of skin traction

- **Buck's extension traction-** is a form of traction where pull is exerted in one plane.
- It is used when partial or temporary immobilization is required, and it is used to provide comfort following injury while awaiting surgical fixation, especially in hip and femur injuries.
- To apply Buck's traction, foam rubber padded straps are placed with the foam surface against the skin on each side of the affected leg.
- A loop of tape is extended beyond the sole of the foot, and a spreader is applied to the distal end of the tape which prevents pressure along the side of the foot.
- The malleolus and proximal fibula are protected with cast padding; this prevents pressure sores and skin necrosis

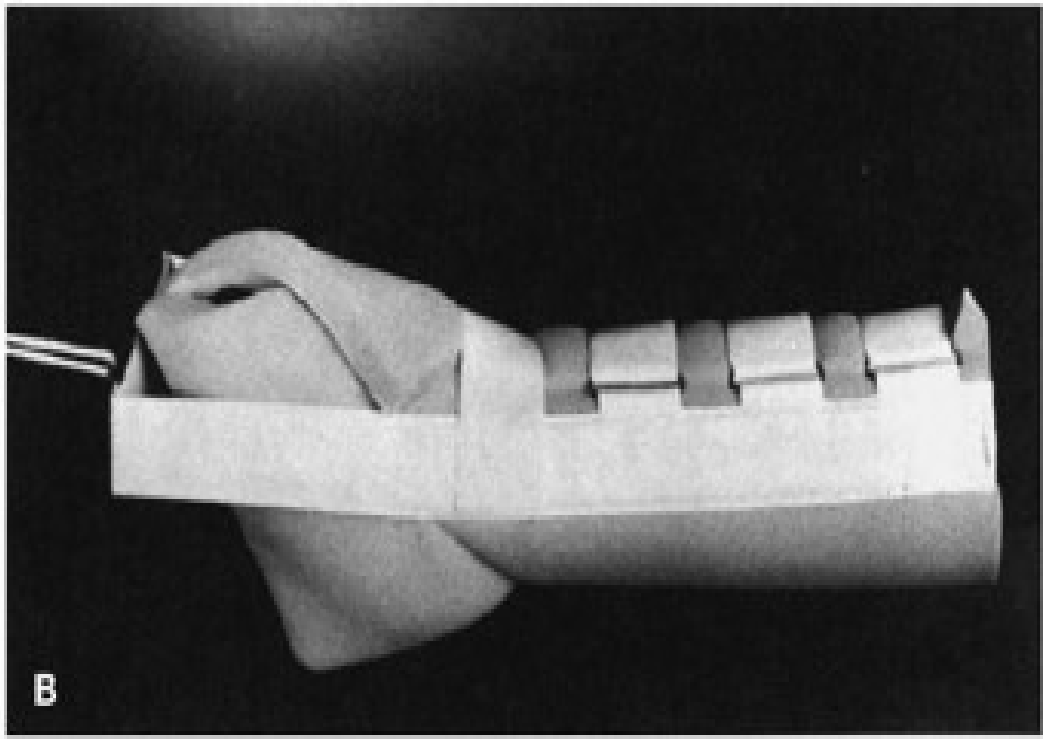

(A) Applying elastic bandage for Buck's extension traction. (B) Prepadded boot that may be used in Buck's extension.

- **Russell's traction-** it is used to stabilize fractured femurs and fractures of the tibial plateau until cell forms. It works by supporting the flexed knee in a sling and applying a horizontal pulling force by use of traction tape and elastic bandage attached to the lower leg.

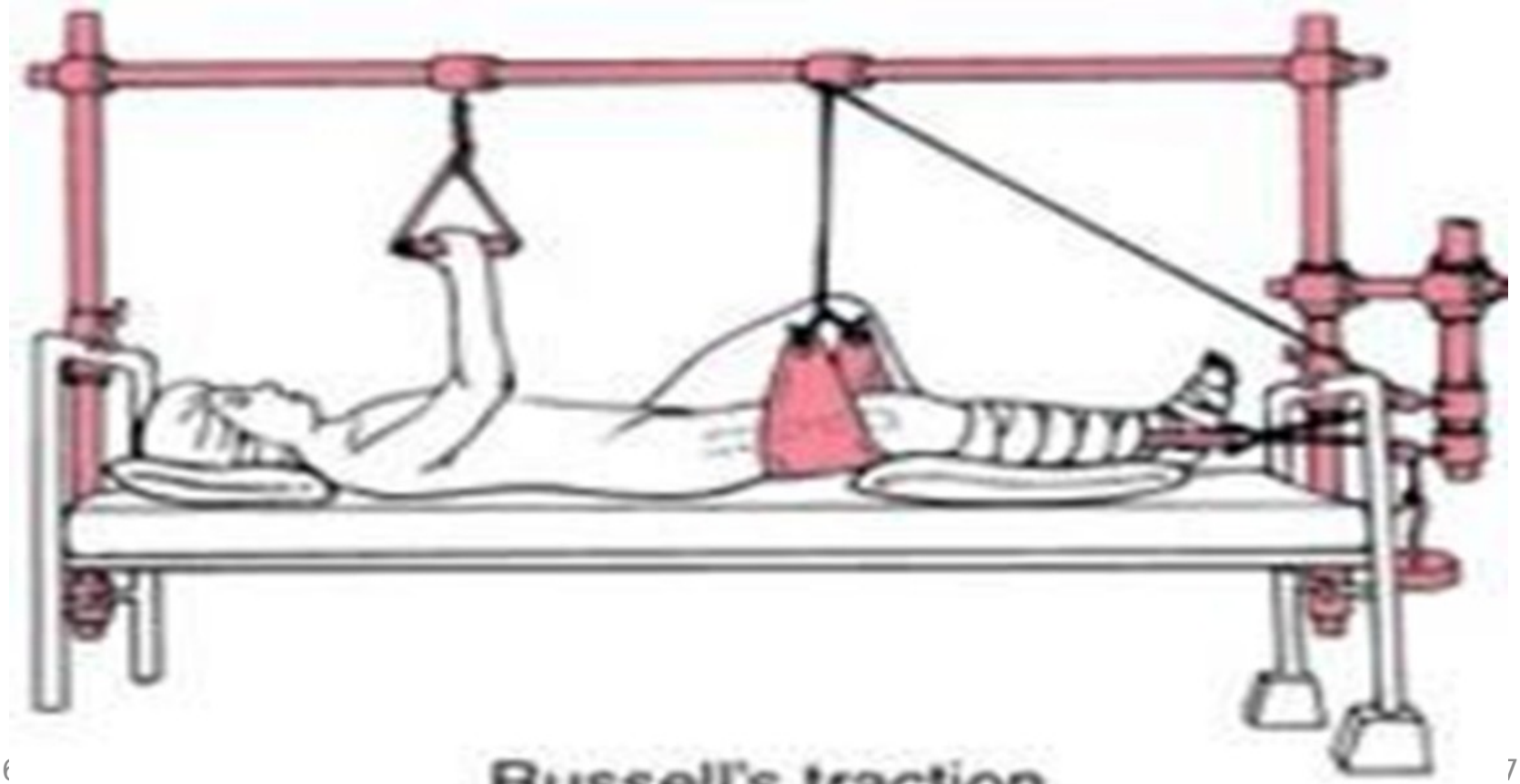

Russell's traction

- **Dunlop's Traction** - used to treat muscle or nerve irritation of shoulders or upper arms. It works in the form of horizontal traction which is applied to the abducted humerous, while vertical traction is applied to the flexed forearm.

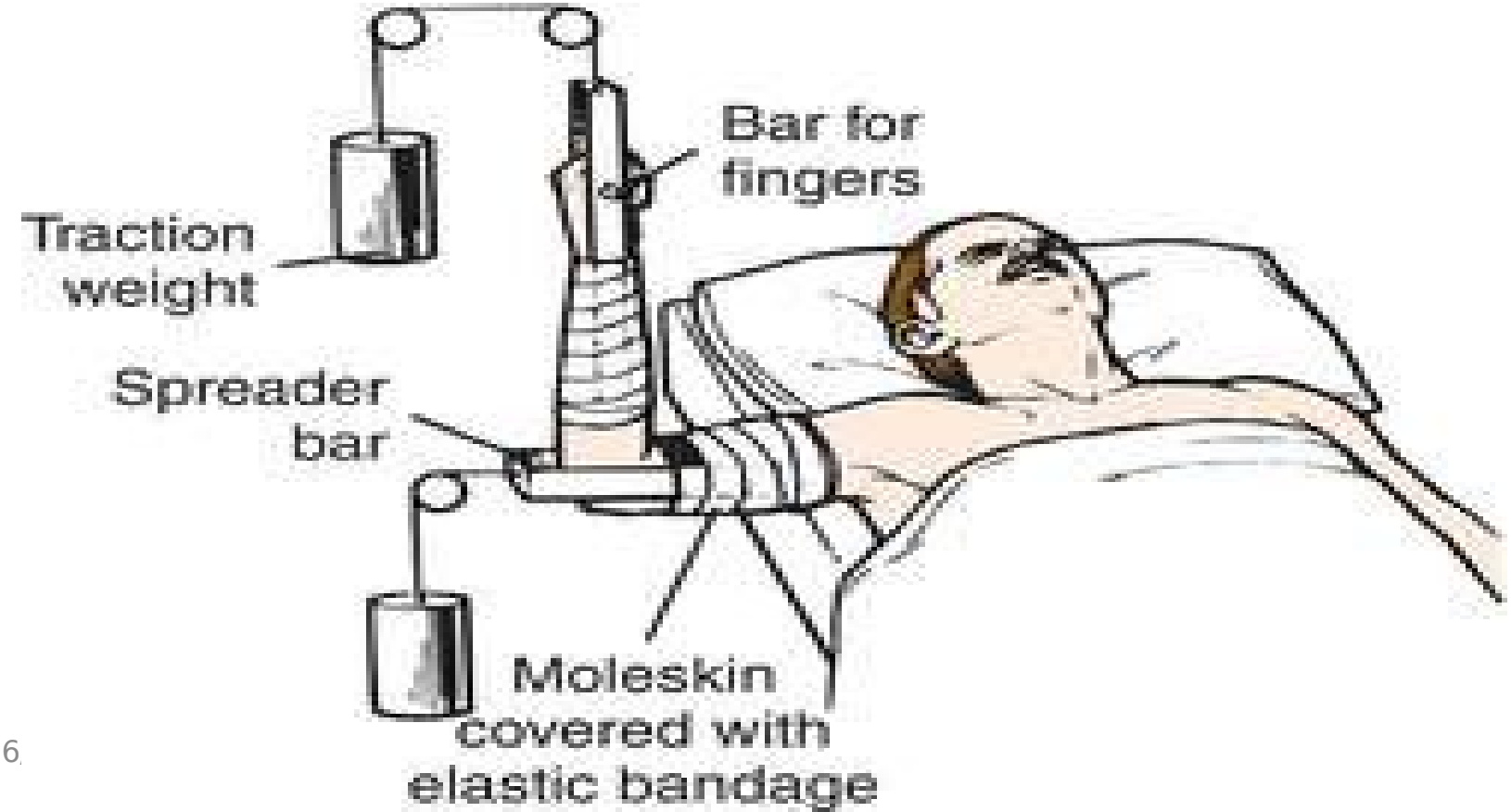

Cont,,,

- **Bryant's traction or Gallow's traction-** used for fracture shaft of femur in children less than 2 years of age. If used in older (more than 2 years) children it causes vascular complication.

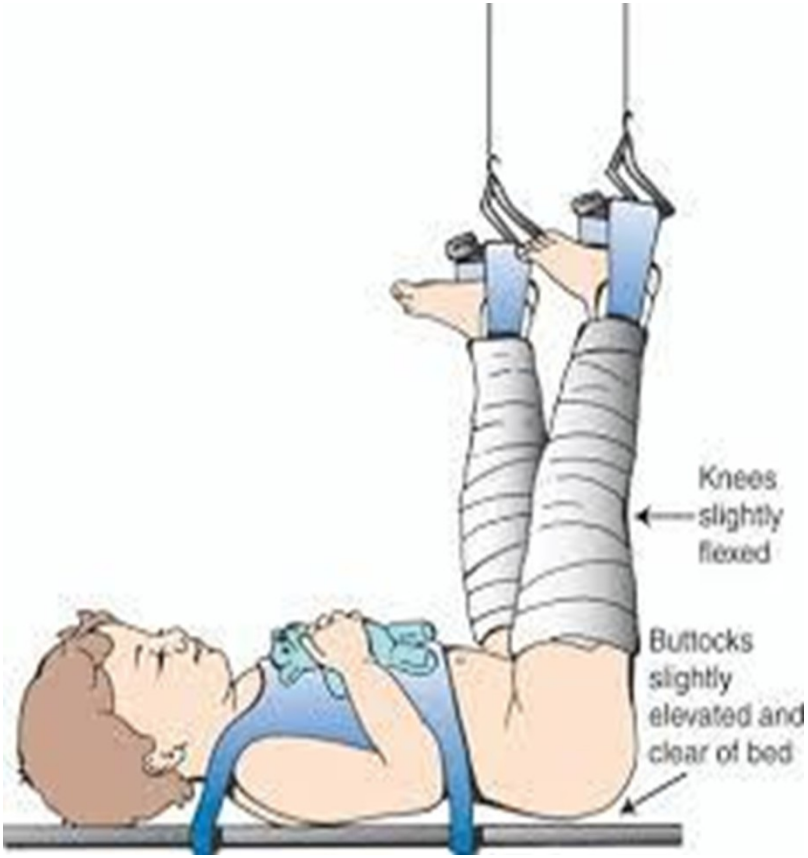

Bryant’s traction

Nursing care for a patient on traction

- Ensure that traction is effective
- Maintain counter-traction
- Avoid wrinkling and slipping of the traction bandage
- Ensure proper positioning of patient i.e. with good body alignment in the middle of the bed, must be maintained to keep the affected limb in a neutral position.
- Reassure the patient to alleviate anxiety.
- Nursing assessment- The body part placed on traction should be assessed for color, temperature, edema, pulse, sensation, movability and skin integrity.

Complication of skin traction

- Skin breakdown
- Nerve pressure
- Circulatory impairment

Skeletal traction- is applied by use of metal pins, wires, or screws that inserted through the bone distal to the fracture. This allows for longer traction time and heavier weights (7-12kgs) to aid in bone re-alignment.

- **<u>Indications Skeletal Traction</u>**

  Adults requiring > 5kg traction

  Skin damage requiring dressings

  Long term traction required

Types of skeletal tractions

- **Halo traction:** To stabilize fractures or displaced vertebrae in cervical and thoracic areas. This is usually always used in adults with broken necks if surgery is not performed immediately post injury.

a) **Balanced suspension traction-** suspends and immobilizes a leg without applying traction to the body. May be applied to hip, tibia, fibula or femur. The leg is supported by a Pearson attachment and a Thomas splint. A Thomas splint is a padded ring that fits around the upper leg while the Pearson attachment meets the Thomas splint at the knee and supports the lower leg. A canvas sling may be used to further support the lower leg. Balanced suspension traction is used to stabilize fractures of the femur and requires an invasive procedure in which pins, screws or wires are surgically installed. Weights used in skeletal traction generally range from 25-40lbs (11-18kg)

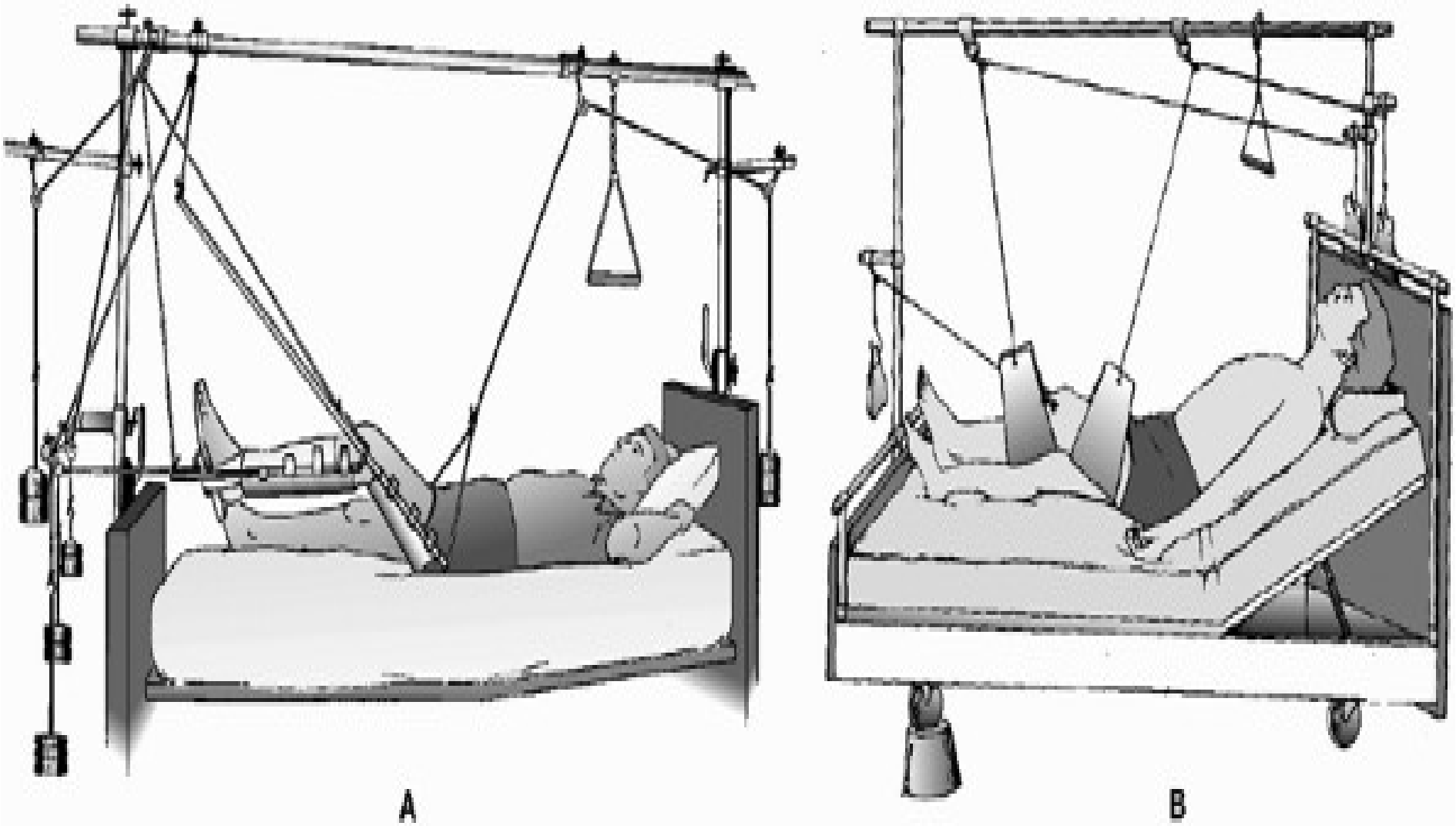

Balanced skeletal traction using (A) Thomas leg splint and Pearson attachment, and (B) slings for support and suspension.

- **Femoral traction 90/90-** most commonly used traction for complicated fractures of the femur. A pin or wire is applied through the distal femur; the lower leg may be casted. The thigh is suspended in the vertical plane by weight traction pulling vertically upwards. The ill effect of gravity as the cause of backward angulation of the fragments is thus eliminated. Most effective in children older than 6 yea

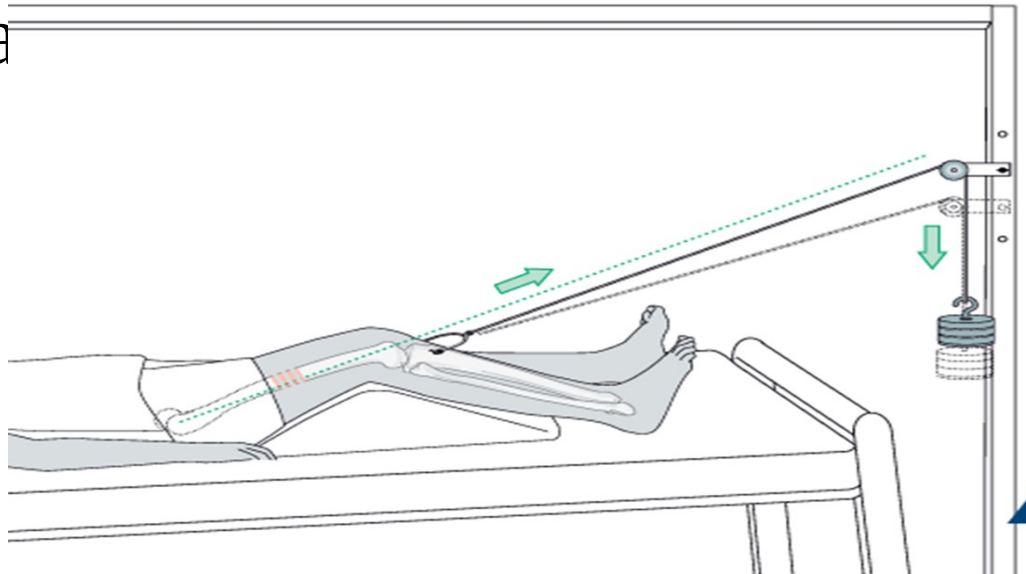

- **Manual traction-** applied by hands temporarily

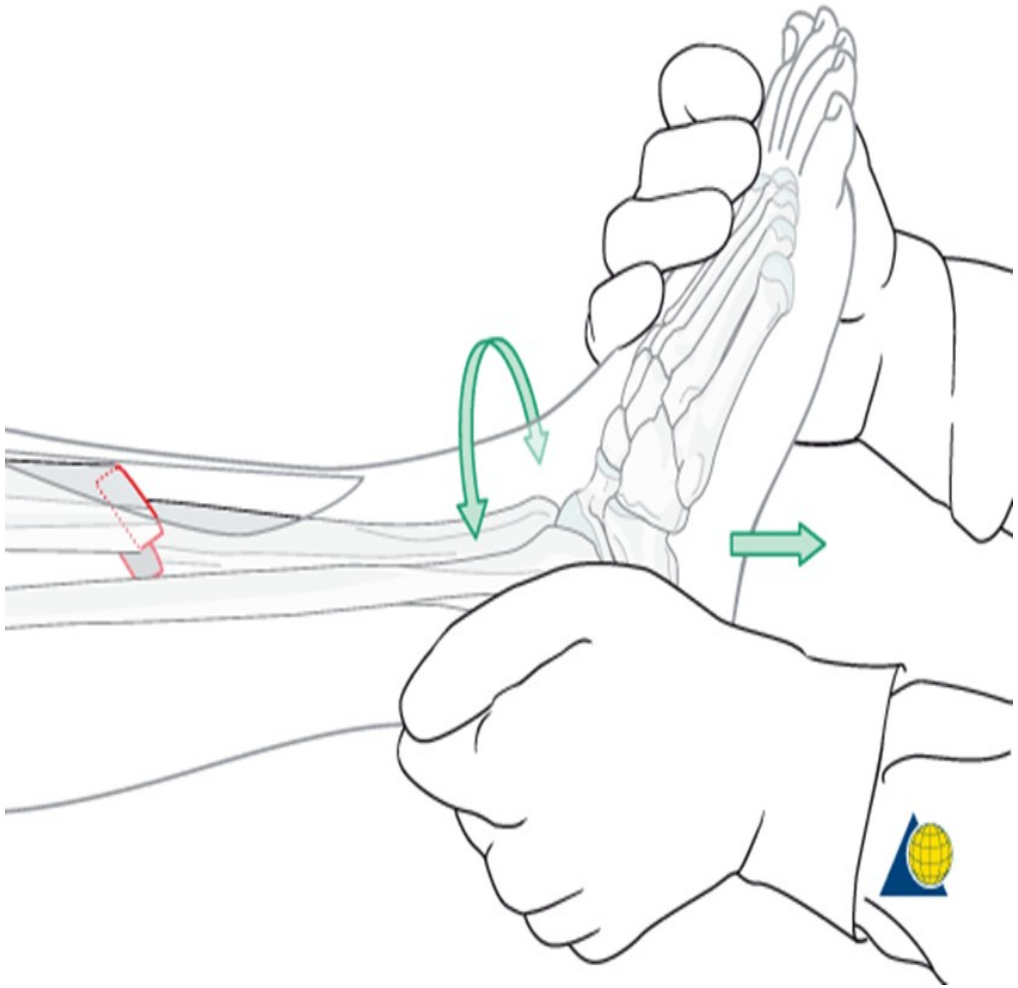

Spinal decompression traction- Spinal traction as a means of spinal decompression is often applied without directly touching bones as other methods of traction do. This is sometimes isolated inside-out by inflatable girdles or use of the transversus abdominis muscle

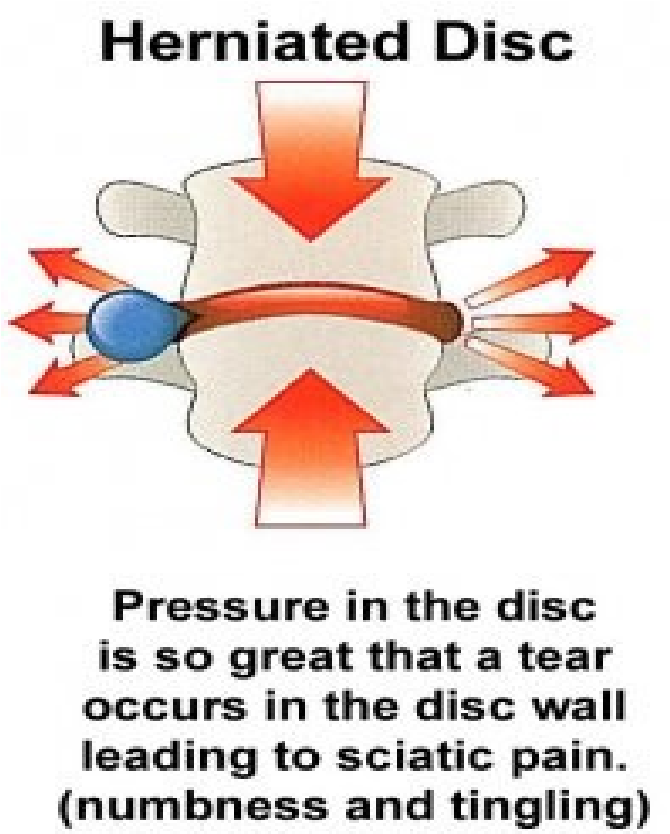

- **<u>Nursing care of a patient on skeletal traction</u>**

a) Maintain effective traction by ensuring that the ropes are in the wheel grooves of the pulley and that the weights hang freely
b) Maintain alignment and position
c) Prevent skin breakdown by assessing pressure areas
d) Monitor neurovascular status
e) Provide pin site care to maintain muscle strength, tone, prevent infection and promote circulation

Complications

- Pressure ulcers
- Pneumonia
- DVT
- Constipation and anorexia
- Infection.

Open Reduction.

- Some fractures require open reduction. Through a surgical approach, the fracture fragments are reduced.
- Internal fixation devices (metallic pins, wires, screws, plates, nails, or rods) may be used to hold the bone fragments in position until solid bone healing occurs.
- These devices may be attached to the sides of bone, or they may be inserted through the bony fragments or directly into the medullary cavity of the bone.
- Internal fixation devices ensure firm approximation and fixation of the bony fragments.

Open reduction and internal fixation

Open reduction and internal fixation of displaced, comminuted subtrochanteric left femur fracture with an intramedullary rod, locking screws and a trochanteric rod

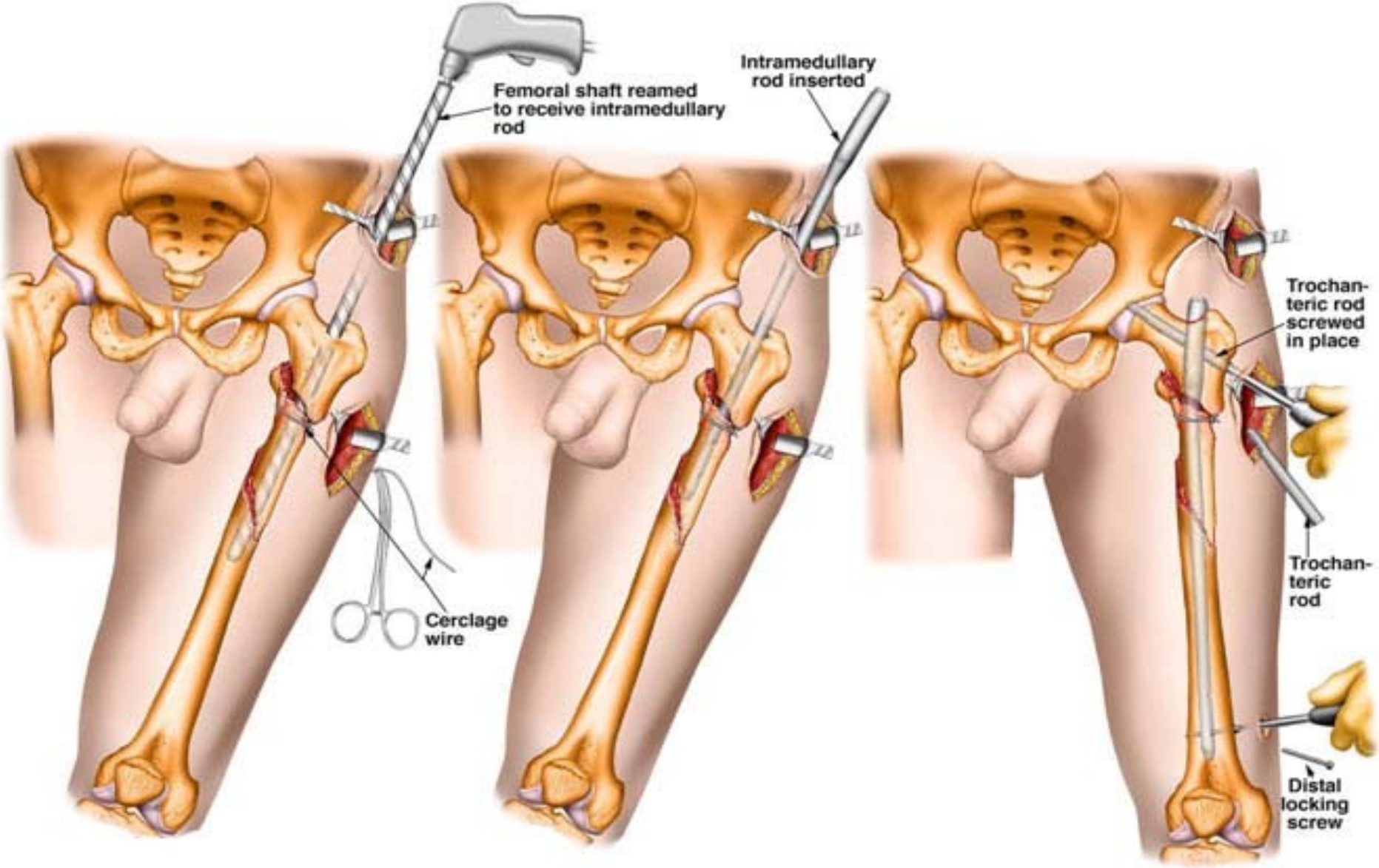

Right Leg Fractures with Open Reduction Internal Fixation Procedure

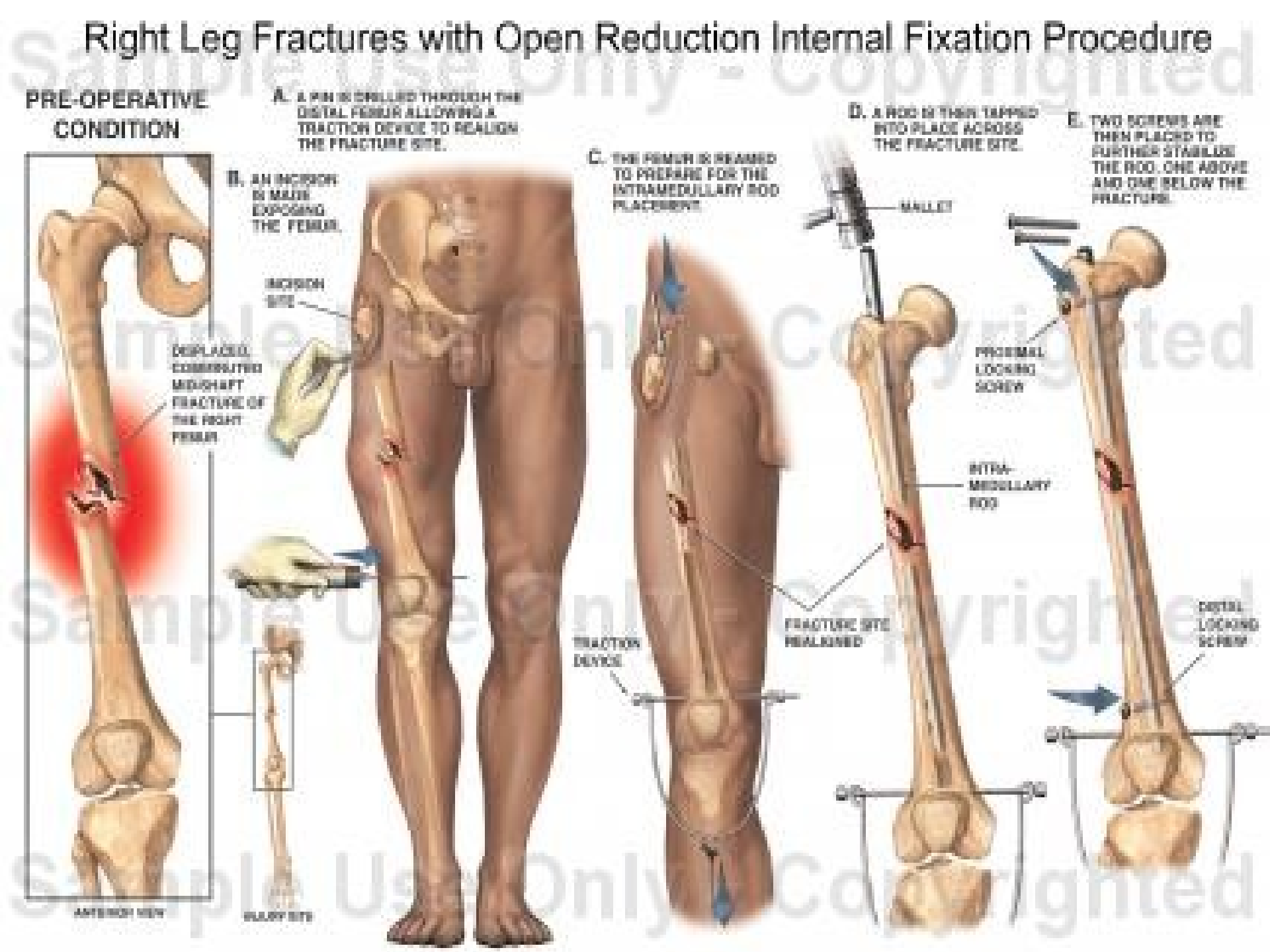

Sample Use Only - Copyrighted

External Fixation

In this type of operation, metal pins or screws are placed into the broken bone above and below the fracture site. The pins or screws are connected to a metal bar outside the skin. This device is a stabilizing frame that holds the bones in the proper position while they heal.

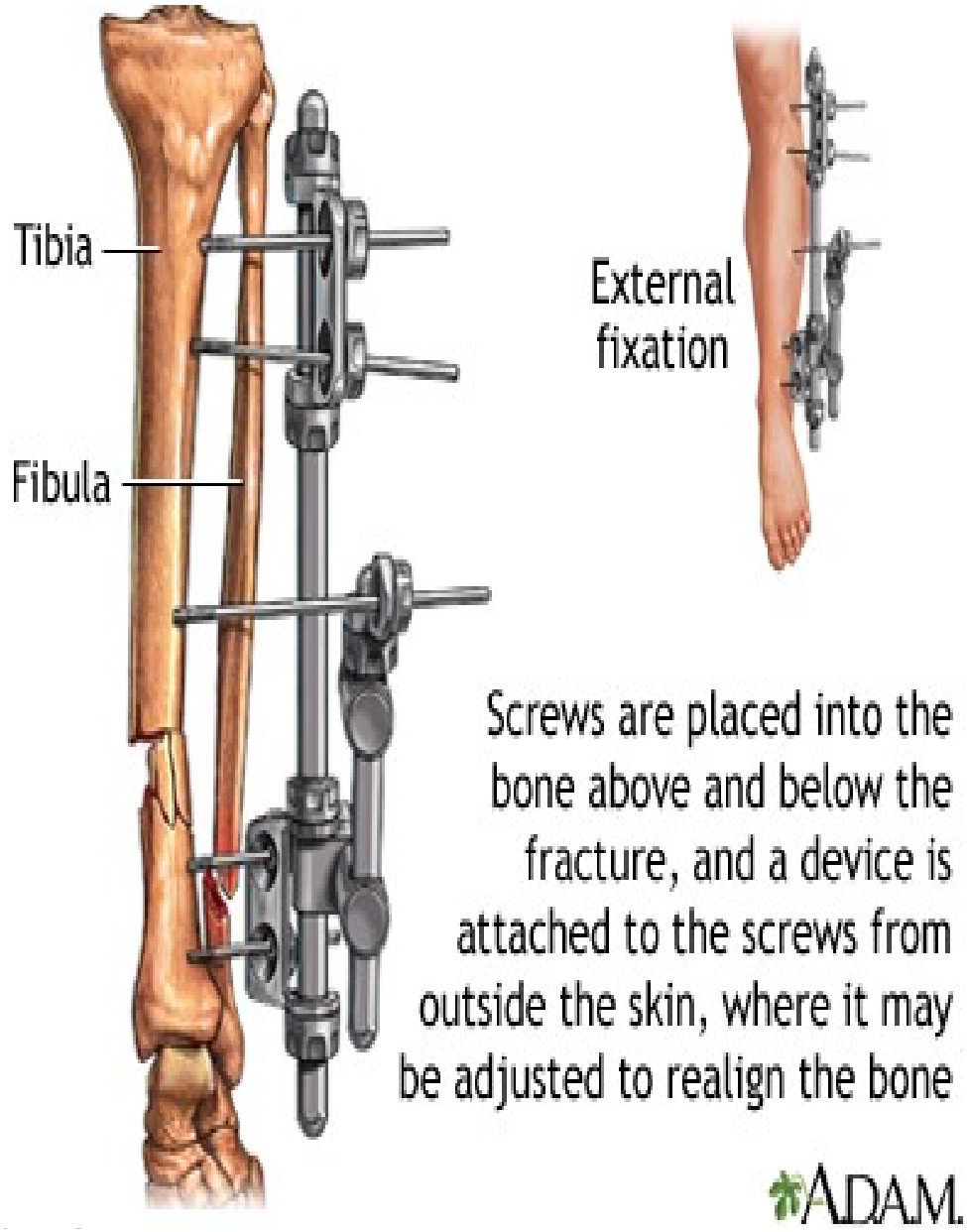

External fixation

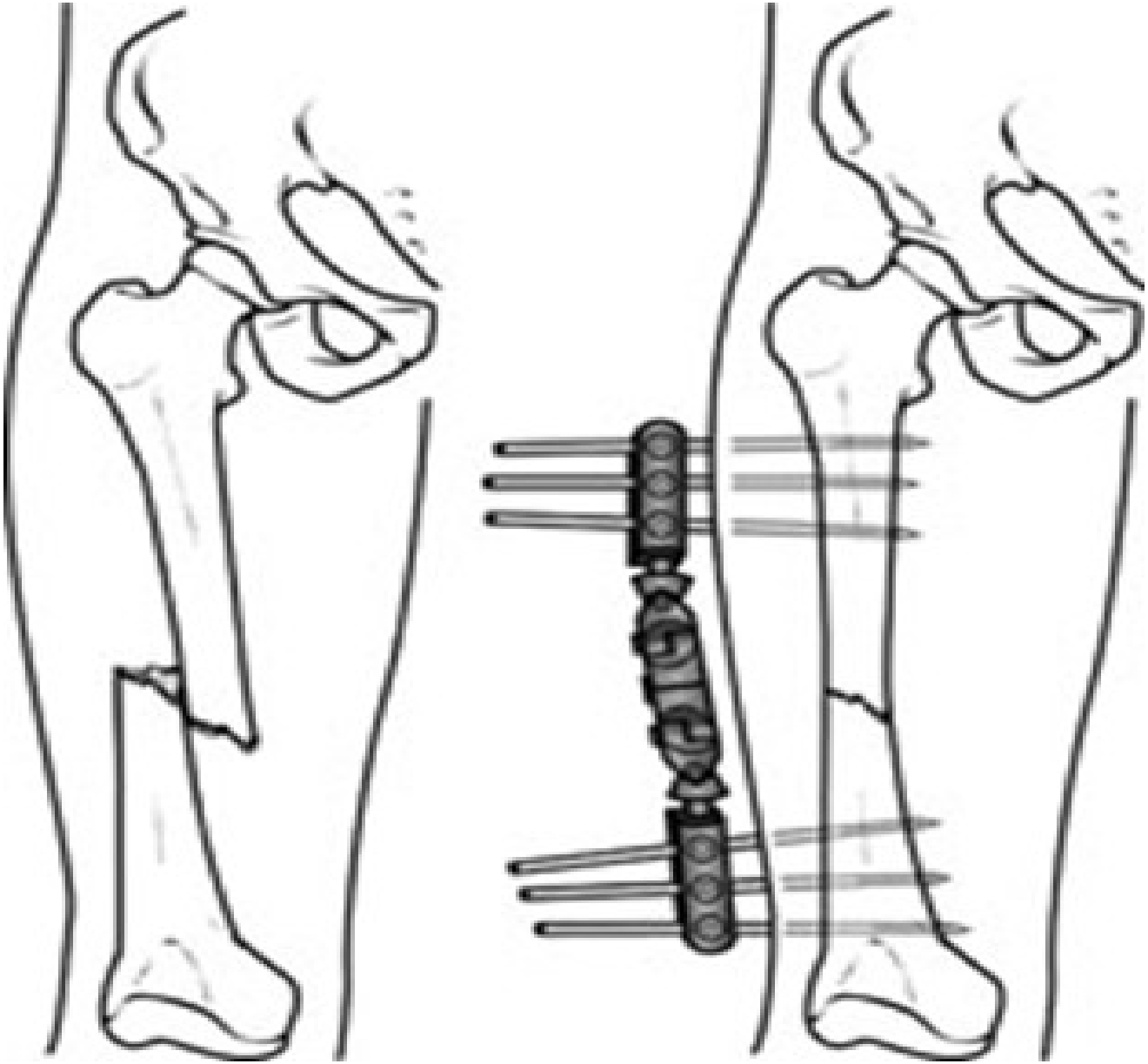

IMMOBILIZATION

- After the fracture has been reduced, the bone fragments must be immobilized, or held in correct position and alignment, until union occurs.
- Immobilization may be accomplished by external or internal fixation.
- Methods of external fixation include bandages, casts, splints, continuous traction, and external fixators.
- Metal implants used for internal fixation serve as internal splints to immobilize the fracture.

- **Cast Immobilization-** A plaster or fiberglass cast is the most common type of fracture treatment, because most broken bones can heal successfully once they have been re-positioned and a cast has been applied to keep the broken ends in proper position while they heal.
- **Functional Cast or Brace-** The cast or brace allows limited or "controlled" movement of nearby joints. This treatment is desirable for some, but not all, fractures.

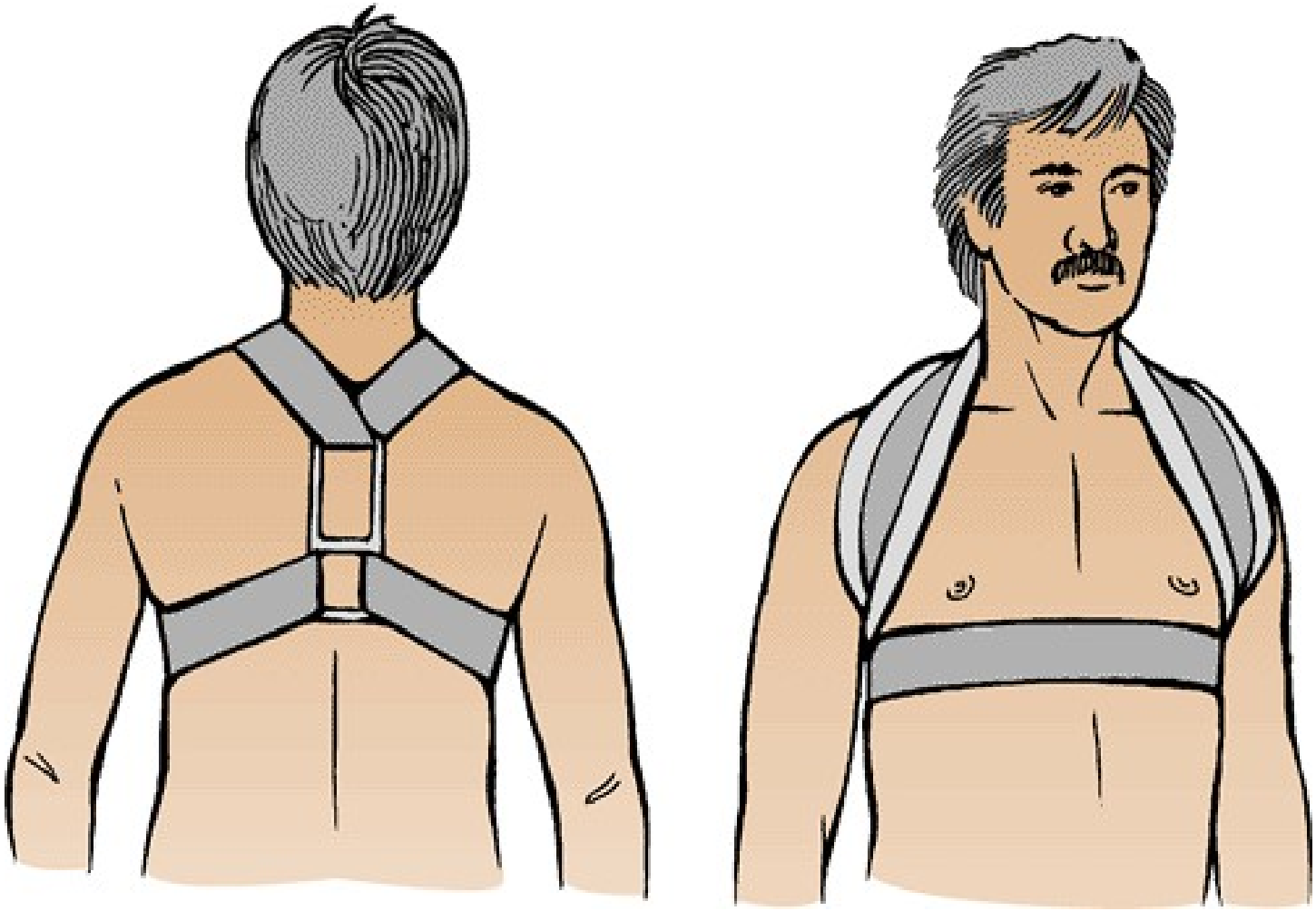

Method for immobilizing a clavicular fracture with a clavicular strap.

cast



Immobilization of fracture of upper humerus with conventional sling and

Braces

MAINTAINING AND RESTORING FUNCTION

- Reduction and immobilization are maintained as prescribed to promote bone and soft tissue healing.
- Swelling is controlled by elevating the injured extremity and applying ice as prescribed.
- Neurovascular status (circulation, movement, sensation) is monitored, and the orthopedic surgeon is notified immediately if signs of neurovascular compromise are identified.
- Restlessness, anxiety, and discomfort are controlled with a variety of approaches, such as reassurance, position changes, and pain relief strategies, including use of analgesics.

- Isometric and muscle-setting exercises are encouraged to minimize disuse atrophy and to promote circulation.
- Participation in activities of daily living (ADLs) is encouraged to promote independent functioning and self-esteem

Factors That Enhance Fracture Healing

- Immobilization of fracture fragments
- Maximum bone fragment contact
- Sufficient blood supply
- Proper nutrition
- Exercise: weight bearing for long bones
- Hormones: growth hormone, thyroid, calcitonin, vitamin D, anabolic steroids

Factors That Inhibit Fracture Healing

- Extensive local trauma and bone loss
- Inadequate immobilization
- Space or tissue between bone fragments
- Infection or local malignancy
- Metabolic bone disease (e.g. osteoporosis)
- Avascular necrosis
- Intra-articular fracture (synovial fluid contains fibrolysins, which lyse the initial clot and retard clot formation)
- Age (elderly persons heal more slowly)
- Corticosteroids (inhibit the repair rate)

Complications of fractures

visceral injury.1

vascular injury.2

compartment syndrome.3

nerve injury.4

infections .5

hemarthrosis.6

- There is no accepted time for a complication to be considered ‘early’, but the term is usually applied to complications that occur during the acute phase of treatment.

1. Visceral Injury:

Fractures around the trunk are often complicated by visceral injury.

E.g. Rib fractures are associated with life threatening pneumothorax or with spleen, liver injuries.

E.g. Pelvic injuries are associated with bladder or urethral rupture and cause sever hematoma in the retroperitoneum .

Surgery of visceral injuries should take precedence over the treatment of fracture.

Rib Fracture and Pneumothorax with Placement of a Chest Tube to Re-inflate the Lung

Copyrighted Materials.

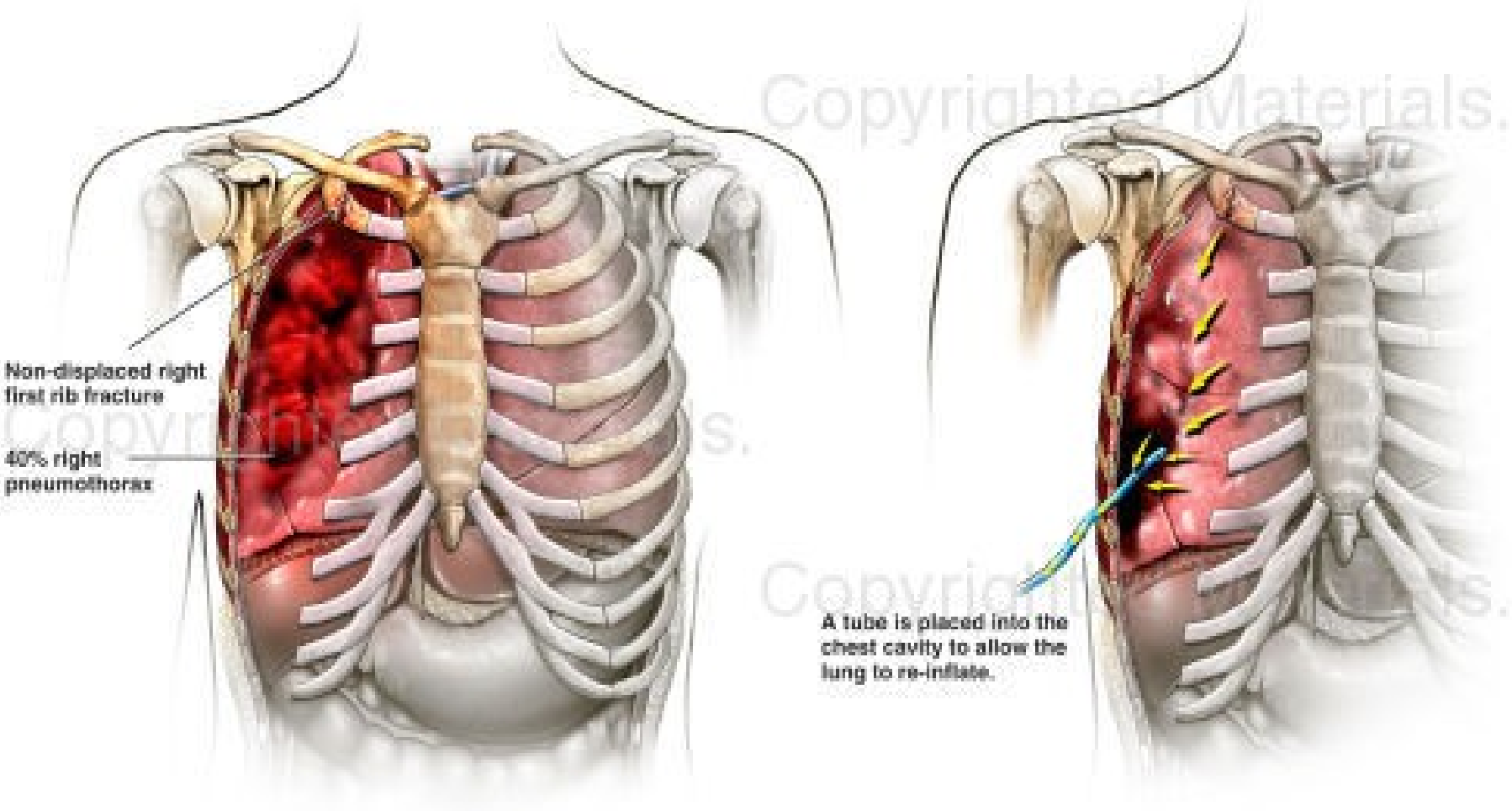

Pre-operative Conditions **Intra-operative Conditions**

Anterior cut-away view of the thorax

2. Vascular Injuries:

Most associated with injuries around knee, elbow, humerus and femoral shaft.

Commonly associated with high-energy open fractures.

They are rare but well-recognized.

Cause : From initial trauma or from bone fragment

Mechanism of injuries:

** The artery may be cut or torn.

** Compressed by the fragment of bone.

** normal appearance with intimal detachment that lead to thrombus formation.

** segment of artery may be in spasm.

Clinical features :

Classical presentation of ischemia 6 *P*s:
Pain , **P**allor, **P**ulseless , **P**aralysis , and **P**araesthesia and Positive passive stretch test
X-ray: suggest high-risk fracture.
Angiogram should be performed to confirm diagnosis.

Fractures commonly associated with vascular injury.

Vessel	Injury
subclavian	1st rib fracture
Axillary	Shoulder dislocation
Brachial	Humeral supracondylar fracture
Brachial	Elbow dislocation
Presacral and internal iliac	Pelvic fracture
Femoral	Femoral supracondylar fracture
Popliteal	Knee dislocation
Popliteal or its	Proximal tibial fracture

yegondomkips@gmail.com

Management

This is an emergency because the effect of ischemia especially on the muscle is irreversible after 6 hours.

1. Temporary vascular shunt to perfuse distal limb.
2. Skeletal stabilization – temporary external fixation often used.
3. Definitive vascular repair.
4. Staged definitive skeletal internal fixation if required.

3. Nerve injury:

It’s more common than arterial injuries.

- The most commonly injured nerve is the radial nerve in its groove or in the lower third of the upper arm especially in oblique fracture of the humerus.
- Common with humerus, elbow and knee fractures
- Most nerve injuries are due to <u>tension neuropraxia.</u>

Closed Injuries

- The nerve is rarely severely affected (just neuropraxia or axontmesis) and spontaneous recovery is usually the role.
- If not; the nerve should be explored because it sometimes trapped between the fragment and occasionally it is found to be divided and more likely to be completely injured.
- And should be explored during wound debridement or in 2nd operation.

Open Injuries

- A complete lesion(neurotmesis) is more likely, the nerve is explored during wound debridement and repaired, either then or 3weeks later by nerve suturing and grafting.

nerve	Injury
Axillary	1. Shoulder dislocation
Radial	2. Humeral shaft fracture
Median	3. Lower end of radius
Radial or median(ant.interosseous)	4. Humeral supracondylar (esp. children)
Ulnar	5. Medial condyle
Ulnar	6. Elbow dislocation
Sciatic	7. Hip dislocation
Peroneal	8. Knee dislocation
Peroneal	9. Fracture of fibular neck

4.Compartment syndrome: :

Most commonly in forearm and calfs.
Muscles are arranged in different compartments and surrounded by one fascia , this arrangement called osteofascial compartment.
Compartment syndrome occurs when muscle swells within osteofacial compartment and occludes its blood supply >> infarction and late ischemic contracture.
Trauma is the most common cause. Reasons that lead to increase the pressure inside:
1. Bleeding
2. Edema
3. Infection

- Fracture of the arm and leg can give rise to severe ischemia even if there is no damage to major vessel.
- Bleeding or edema will increase the pressure within one of the osteofascial compartments, this lead to decrease in capillary blood flow which in turn leads to muscle ischemia, further edema, still greater pressure, and yet more profound ischemia….vicious circle.

- After 12 hours or less, this vicious circle ends in necrosis of nerves and muscles within the compartment.
- Nerves are capable of regeneration, but the muscle once infarcted can never recover and are replaced by fibrous tissue. This condition is called ***volkmann's ischemic contracture***.

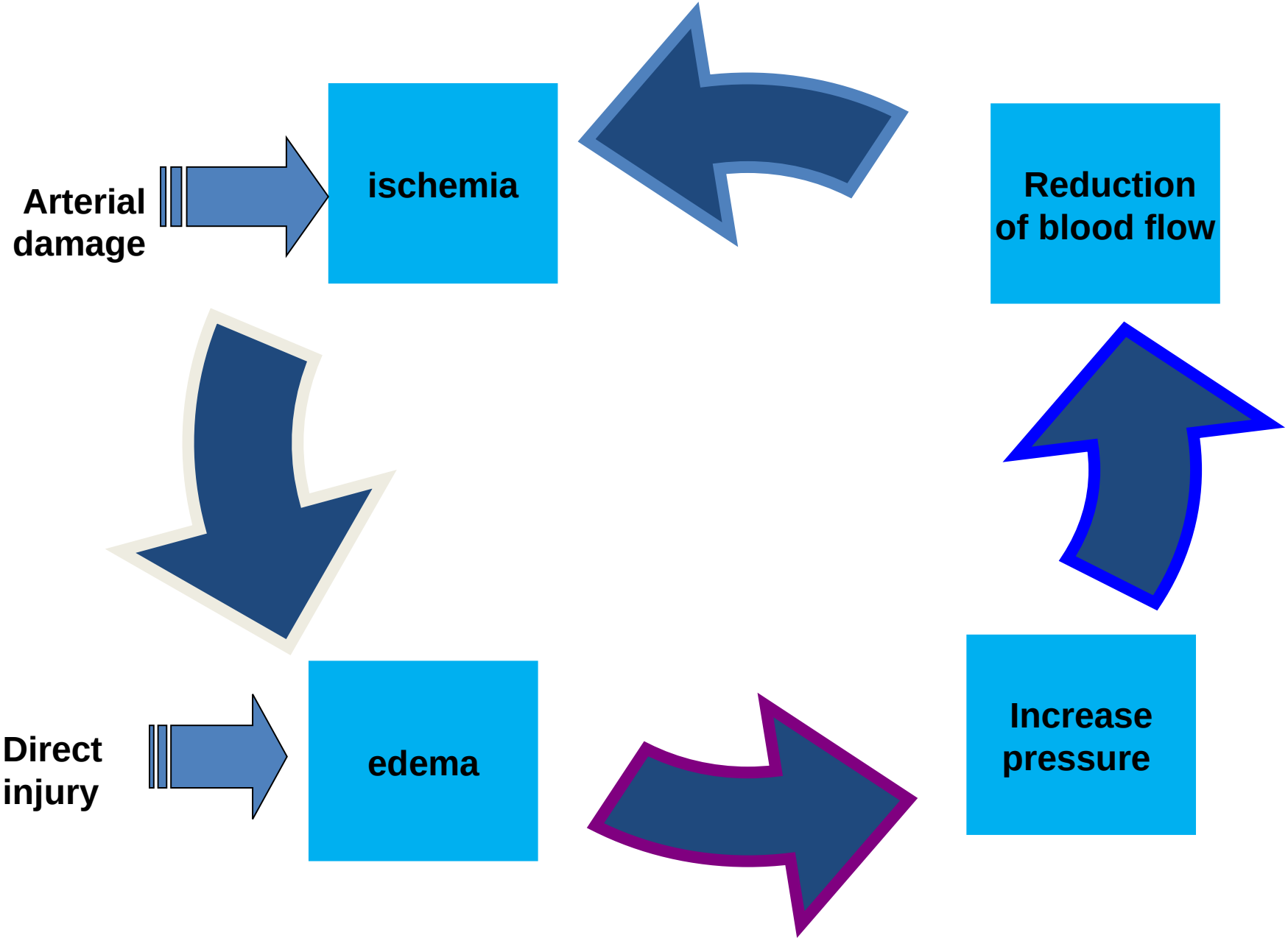
Arterial damage
ischemia
Reduction of blood flow
Increase pressure
edema
Direct injury

- Distal pulses and neurological functions are normal until very late.
  Muscle will be dead after 4-6 hrs of total ischemia so there is no time to lose!

When do we have to suspect compartment syndrome?

1. High-risk injuries-fracture of the elbow
- fracture of the forearm
- fracture of the proximal third of the tibia

2.Predisposing factor: operation (internal fixation) ,infection.

3.Classical feature of ischemia (5ps)

4. very painful, swollen, tense limb.

Don't wait for the obvious sings of ischemia to appear. If you suspect An impending compartment syndrome, start treatment straightaway

Cont..

5. the muscle should be tested by stretching; if the pain increase then this goes with compartment syndrome.

6. In doubtful cases, the diagnosis is confirmed by measuring the compartment pressure by using a catheter which is introduced into the compartment close to the level of fracture.

- A differential pressure (the difference between diastolic and compartment pressure) of **less than 30mmHg** is an indication for immediate decompression

Treatment :

1. Decompression ….by Immediate open fasciotomy (open all compartment through medial and lateral incisions) and left open for 2 days

2. If there is muscle necrosis , debridement can be done

3.if tissue is healthy the wound can be sutured, or skin-grafted. or the wound is left to heal by secondary intention

4. Limb should be examined every 15 min for 2 hours if there is no improvement , or if the pressure falls below 30 …

5.Haemarthrosis

*Bleeding into a joint spaces.

*Occurs if a joint is involved in the fracture.

Presentation:

swollen tense joint; the patient resists any attempt to moving it.

Treatment :

blood aspiration before dealing with the fracture; to prevent the development of synovial adhesions.

6.Infection:

*usually seen in open fractures; rarely with closed fractures unless opened by operation (ex; internal fixation).

*Open fracture in 6 hrs the risk of infection increases up to 10x.

*All open fracture should be treated by prophylactic antibiotics ,

*appropriate early management; wound excision and debridement, skeletal stabilization and wound closure.

*Post-traumatic bone infection is the most common cause of chronic osteomyelitis

*Infection may be early within days after surgery or late occurring months after surgery